

# Developmental dysplasia of the hip (DDH)



## Background

Developmental dysplasia of the hip (DDH) is the most common paediatric hip condition affecting 0.4% of live births. We operate a selective ultrasound screening policy in Nottingham performing ultrasound assessment of babies with clinical concerns over DDH or risk factors.

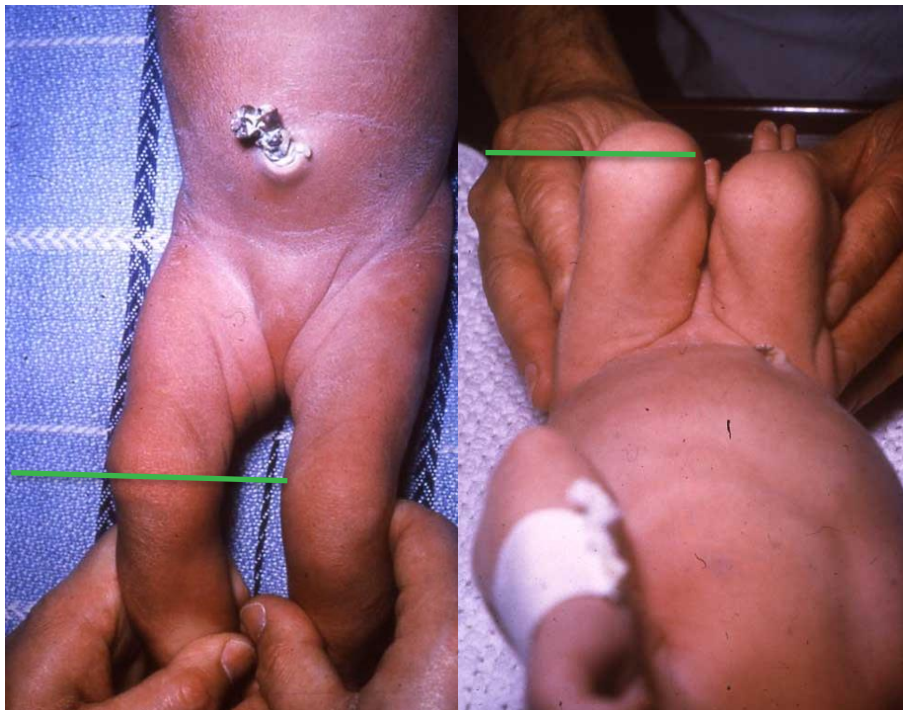
The risk factors for DDH are:

- Breech presentation
- Family history of an infant requiring treatment for DDH
- Talipes

## Examination

The clinical examination of a child for DDH should include an assessment of leg length discrepancy, combined abduction in flexion and stability of the hip.

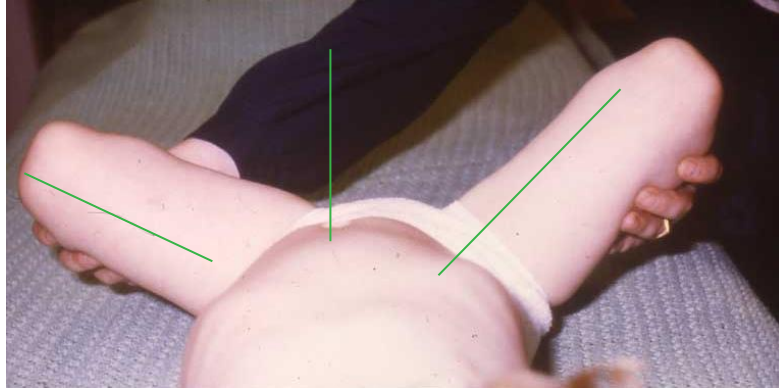
Leg length discrepancy should be assessed first with the legs in extension with the ankles held together. Care must be taken to make sure that the legs are square to the pelvis to prevent false disparity. If one leg is shorter, the knee will appear to be more proximal than the other side. After this the knees should be flexed to 90°, with the ankles held together. Looking from the end of the bed the examiner should be able to see if one knee is lower than the other. It is generally easier to see in this position than with the legs in extension.



*Pictures of a child with a right dislocated hip. Left: Leg length assessment in extension shows the right knee lies more proximally than the left. Right: Leg length assessment in flexion shows more clearly the right knee lying lower than the left.*



Combined abduction in flexion will show any restriction of hip movement due to a tight adductor tendon or a dislocated hip.



*Restricted abduction in flexion of the right hip.*

The tests for hip instability are Barlow and Ortolani. In the Barlow test, the leg is held in flexion above  $90^\circ$  and adducted across the midline. Gentle force is applied diagonally back and out to try to push the hip out of the back of the acetabulum. Unstable hips will sublux or dislocate on this test.

The Ortolani test reduces a dislocated hip. Keeping the hip in more than  $90^\circ$  of flexion, the hip is maximally abducted. If the dislocated hip is reducible it should slip back in to the joint with a loud clunk, the examiner feeling a big shift in movement and seeing a change in the shape of the soft tissues in the thigh. If the hip is not reducible then there will be restricted abduction as shown above.

### Examination findings per age

Newborns may present with a leg length discrepancy, restricted abduction or frank instability signs. By the age of six to ten weeks, the instability signs begin to resolve as the soft tissues tighten.

In children of three months or older, leg length assessment and combined abduction in flexion is by far the most accurate means of detecting DDH.

In children of walking age, the leg length discrepancy may be more obvious when standing. There is a Trendelenberg (waddling) gait as the child swings their trunk from side to side as they walk to compensate for hip girdle weakness.



## Referral criteria

Urgent referral should be made for children under the age of five months if you find:

- Leg length discrepancy
- Restricted abduction in flexion
- Frank instability of the hip on Ortolani or Barlow tests

An urgent referral to the hip instability clinic should be emailed through immediately to [NUHNT.centralappointments@nhs.net](mailto:NUHNT.centralappointments@nhs.net) or faxed to 0115 875 4613 at QMC. An appointment should be sent within two weeks of referral.

Routine referrals for children under the age of five months should be sent through to paediatric central appointments at QMC and an appointment should be sent out within six to eight weeks. Routine referrals are for:

- Breech presentation
- Family history of needing treatment for DDH as an infant
- Talipes
- Reproducible click on examination

For children over five months, ultrasound is rarely effective. If there are clinical concerns regarding DDH in a child over this age then an AP pelvis X-ray should be requested. If the referrer writes clearly on the request that the purpose of the X-ray is ?DDH then it will be accepted and reported. If abnormality is seen on X-ray then the child should be referred to orthopaedics.